

BRIEF REPORT

Fatal Hepatic Veno-Occlusive Disease With Fibrinolysis as the Cause of Death During Preoperative Chemotherapy for Nephroblastoma

Srdana Čulić, MD,^{1*} Jan de Kraker, MD, PhD,² Dubravka Kuljiš, MD,¹
 Ivana Kuzmić, MD,³ Marjan Saraga, MD,¹ Vida Čulić, MD,¹
 Livio Balarin, MD, PhD,¹ and Dragan Primorac, MD, PhD¹

Key words: dystrophic children; chemotherapy; veno-occlusive disease

INTRODUCTION

Small and dystrophic children are at high risk of developing hepatic veno-occlusive disease (VOD) during the first 3 weeks of treatment with dactinomycin [1]. It is characterized by a rapid onset of weight gain, ascites, hepatomegaly, right upper quadrant pain, jaundice, and oliguria. Hepatic encephalopathy, fulminant hepatic failure, and respiratory distress complete the full-blown clinical picture [2]. The pathogenesis of VOD has been attributed to toxic damage of the sinusoidal endothelium, allowing erythrocyte extravasation into the space of Disse, activation of the coagulation cascade, and downstream accumulation of debris in the central vein [3].

This syndrome developed in a 2-year 9-month-old boy who was admitted to our department with a history of an abdominal mass. He was born as the second child of a twin after 35 weeks of pregnancy. With his birth weight of 1,500 g he was premature and dysmature. His early life was complicated by respiratory distress syndrome, staphylococcus sepsis, and severe hyperbilirubinemia for which he received an exchange transfusion. At a routine check-up 2 years later, a left-sided abdominal mass was found and on ultrasound (US) examination, an intrarenal tumor was seen. No other abnormalities were found during work-up, so that chemotherapy was initiated following SIOP Nephroblastoma Study protocol No. 93-01. It calls for preoperative dactinomycin and vincristine (VCR). Following the second VCR dose, the boy became febrile for 3 days (Table I). One day later he vomited five times. Seven days later he received the second course of VCR and dactinomycin which was tolerated well. He had no signs of liver dysfunction at that time. Soon after the administration of the fourth VCR dose, a distinct pattern of VOD appeared: right upper quadrant pain, jaundice, hepatomegaly, ascites, oliguria, and weight gain. Coagulation studies revealed depression of factors II, V, VII, IX, and X with normal values of factor VIII. Elevated liver enzymes and fibrin degradation products were ob-

TABLE I. Preoperative Chemotherapy and Clinical Follow-Up†

Days	0	7	14	21
Chemotherapy				
VCR (1.5 mg/m ²)	*	*	*	*
Dactinomycin (15 µg/m ²)		***		***
Temperature		***		****
Emesis		*		*
Jaundice				*
Hepatomegaly				****
Ascites				****
Oliguria				****
Weight gain				****
Trombocytopenia		*****		*****

†Asterisks represent either administration of chemotherapy or onset of clinical symptoms; each asterisk shows one day.

served as well. Hepatic encephalopathy or VOD of the brain, fulminant hepatic failure, and respiratory failure ensued rapidly along with signs of liver dysfunction with fibrinolysis, and a bleeding diathesis. He was treated unsuccessfully with heparin, fresh plasma, human albumin, fibrinogen, corticosteroids, and transfusions of erythrocytes and platelets and he died 6 days after appearance of the first symptoms.

The post-mortem examination revealed a SIOP stage I nephroblastoma, ascites (150 ml), and a congested liver (725 g) without visible obstruction of the hepatic veins. The brain was not examined. The liver revealed centrilobular hemorrhagic necrosis (Fig. 1). A reticulin stain showed obliteration of hepatic vein branches by a vary-

¹Department of Pediatrics, University Hospital Split, Split, Croatia

²SIOP Nephroblastoma, Trial and Study Office, Amsterdam, The Netherlands

³Department of Pathology, University Hospital Split, Split, Croatia

*Correspondence to: Srdana Čulić, M.D., University Hospital Split, Department of Pediatrics, Spinčičeva 1, 21 000 Split, Croatia. E-mail: srdjana.culic@st.tel.hr

Received 12 January 1998; Accepted 4 April 1998

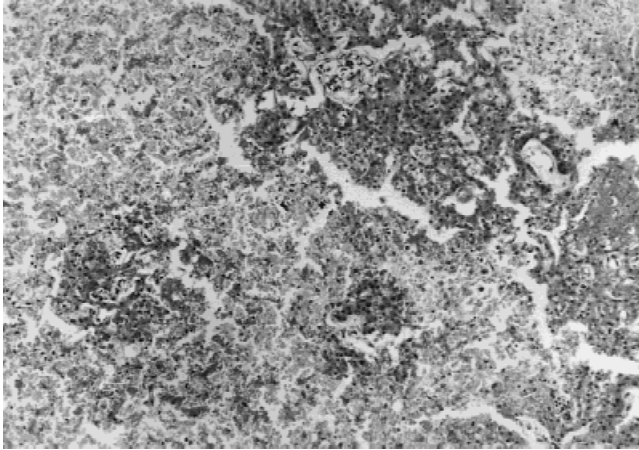


Fig. 1. VOD with centrilobular hemorrhagic necrosis (hematoxylin-eosin stain, $\times 120$).

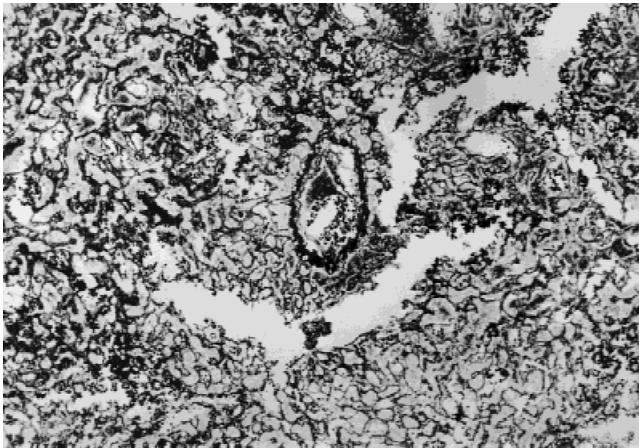


Fig. 2. A reticulin stain reveals marked subendothelial swelling and fine reticulated collagen within the lumen of the central vein (reticulin stain, $\times 250$).

ing amount of subendothelial swelling and some fine but not prominent reticulated collagen (Fig. 2).

Some of the known risk factors for VOD include high-dose anticancer drug- conditioning regimens, leukemia,

or preexisting liver disease. Ortega et al. [4] evaluated 821 patients with rhabdomyosarcoma after administration of VCR, dactinomycin, and cyclophosphamide. They found that 10 of them developed hepatic VOD. They also reported that the highest incidence of VOD has been linked with VCR. Two recent studies [5,6] have shown that most patients who developed VOD after treatment for malignant renal tumors were under 3 years of age. Based on the fatal outcome in our patient, we suggest that prematurity, immaturity, low birth weight, and earlier hepatic infections might also be risk factors for life-threatening VOD. If those factors are present, the doses of preoperative chemotherapy should perhaps be reduced, e.g., to two thirds of the standard amounts. Maximal care and continuous US monitoring of the liver for flow direction in the portal vein might be useful in lessening the risk of a fatal outcome [7].

REFERENCES

1. Ludwig R, Weirich A, Hofmann WJ, et al.: Venous-occlusive disease (VOD) as hepatotoxic side effect of the nephroblastoma SIOP 9 treatment protocol. *Med Pediatr Oncol* 20:434–435, 1992.
2. Kanwar VS, Albuquerque ML, Ribeiro RC, et al.: Venous-occlusive disease of the liver after chemotherapy of rhabdomyosarcoma: Case report with review of the literature. *Med Pediatr Oncol* 124: 334–340, 1995.
3. Cotran RS, Kumar V, Robbins SL (eds): "Pathologic Basis of Disease." Philadelphia: W.B. Saunders Company, 1994.
4. Ortega JA, Donaldson SS, Ivy SP, et al.: Venous-occlusive disease of the liver after chemotherapy with vincristine, actinomycin D and cyclophosphamide for the treatment of rhabdomyosarcoma. A report of the Intergroup Rhabdomyosarcoma Study Group, Children's Cancer Group, the Pediatric Oncology Group and the Pediatric Intergroup Statistical Center. *Cancer* 79:2435–2439, 1997.
5. Trobs RB, Rothe K, Meier T: Hepatic venous-occlusive disease simulating acute abdomen in chemotherapy of Wilms tumors. *Langenbecks Arch Chir* 113:1112–1114, 1996.
6. Kullendorff CM, Bekassy AN: Hepatic venous-occlusive disease in Wilms tumors. *Eur J Pediatr Surg* 6:338–340, 1996.
7. Arndt C, Matsumoto J, Perrault J: Mild reversible venous-occlusive disease of the liver after non-myeloablative chemotherapy documented by ultrasound. *Med Pediatr Oncol* 23:286, 1994.